



Case Report

A Case Report of a Patient with Miller Fisher Syndrome Treated with Traditional Korean Medicine



Hyo Bin Kim, Jeong Kyo Jeong, Myung Kwan Kim, Jae Ik Kim, Ye Ji Lee, Ju Hyun Jeon, Eunseok Kim, Jung Ho Kim, Young Il Kim*

Department of Acupuncture & Moxibustion, College of Korean Medicine, Daejeon University, Daejeon, Korea

ABSTRACT

Article history:

Submitted: June 26, 2018
Revised: July 26, 2018
Accepted: August 3, 2018

Keywords:

acute inflammatory polyneuropathy, case reports, Miller Fisher syndrome, Korean traditional medicine

The aim of this report is to describe improved symptom changes in eye movement disorders and dizziness of a patient with Miller Fisher syndrome after receiving combined Korean medicine treatment (CKMT). A 24-year-old male was diagnosed with MFS accompanied by eye movement disorder, diplopia, and dizziness. For 6 weeks, the patient received acupuncture, electro-acupuncture, pharmacopuncture, herbal medicine, and physical therapy treatment. Visual analogue scale were checked and other outcomes (the range of eye movement, the distance that diplopia appears, diplopia questionnaire) were measured. Following CKMT, the movement of both eyes improved in both the horizontal and vertical direction. Also for diplopia and dizziness, there was a decrease in the visual analogue scale and the distance that diplopia appeared. The present case report suggests that CKMT may have a role in treating eye movement disorders and dizziness in patient diagnosed with MFS.

<https://doi.org/10.13045/jar.2018.00150>
pISSN 2586-288X eISSN 2586-2898

©2018 Korean Acupuncture & Moxibustion Medicine Society. This is an open access article under the CC BY-NC-ND license (<http://creativecommons.org/licenses/by-nc-nd/4.0/>).

Introduction

Miller Fisher syndrome (MFS) is a type of acute inflammatory polyneuropathy, a disease characterized by abnormal muscle coordination, absence of tendon reflexes, and paralysis of the eye muscle. Collier first described it in 1932 as a variant of Guillain-Barre syndrome, and in 1956, Miller Fischer described it as an independent disease with 3 main symptoms [1]. It is reported that in two thirds of MFS patients, respiratory or gastro-intestinal infection precedes, and in an average of 10 days, nervous symptoms start to appear [2]. Diagnosis of MFS is based on 3 characteristic clinical symptoms with examination of serum anti-GQ1b IgG antibody [3]. This study reports on one MFS patient who did not show improvement in eye movement disorder, diplopia, and dizziness upon 5-days of high-dosage steroids, however symptom improvement was observed after CKMT. This study was exempt from IRB deliberation (IRB No.: DJDSKH-18-E-03-1).

Case Report

A 24-year-old male suffered from enteritis from September, 9, 2017, followed after 5 days by diplopia, eye movement disorder, and dizziness. He showed gait ataxia, deep tendon reflex (DTR) hypoactive, and limited eye movement in all directions. Brain magnetic resonance imaging and cerebrospinal fluid examination did not show any abnormalities, and the blood test showed Anti-GQ1b Ab of 1:1,600, diagnosing him as having MFS. During his admission period in OO hospital, high-dosage steroid administration for 5 days did not improve his symptoms. He then visited OO Korean medicine hospital and received combined Korean medicine treatment (CKMT) as an inpatient for 40 days.

Treatment methods

For 6 weeks, the patient received acupuncture, electro-acupuncture, pharmacopuncture, herbal medicine, and physical therapy treatment. Acupuncture needles were inserted at 12 acupoints for 15 minutes: Bilateral BL2, Ex-HN4, TE23, Ex-

*Corresponding author.
Department of Acupuncture & Moxibustion, Dunsan Korean medicine Hospital of Daejeon University, Daejeon, Korea
E-mail: omdkim01@dju.kr

Table 1. Standards for Reporting Intervention in Clinical Trials of Acupuncture.

Item	Detail	Details
1. Acupuncture rationale	1a) Style of acupuncture	Acupuncture treatments were based on Korean medicine theory.
	1b) Reasoning for treatment provided	Textbook of Acupuncture and Moxibustion Medicine
	1c) Extent to which treatment was varied	Treatment was almost the same.
2. Details of needling	2a) Number of needles inserted	12 needles per session
	2b) Names of points used	Bilateral BL2, Ex-HN4, TE23, Ex-HN5, TE17, and ST2
	2c) Depth of insertion	0.5 to 1.0 cm on BL2, Ex-HN4, TE23, Ex-HN5, TE17, and ST2 points
	2d) Response sought	Subjective De-qi sensation
	2e) Needle stimulation	Manual stimulation of rotation, lifting and thrusting
	2f) Needle retention time	0 ~ 15minutes
	2g) Needle type	Dong-bang stainless steel disposable acupuncture needle 0.20 × 30 mm
3. Treatment regimen	3a) Number of sessions	80 sessions
	3b) Frequency/duration	Twice a day for 40 days
4. Other components of treatment	4a) Details of other interventions	electro-acupuncture, pharmacopuncture, herbal medicine, and physical therapy treatment
5. Practitioner background	5) Description of participating acupuncturists	2 Korean medicine doctors. 1) Resident trainee in acupuncture and moxibustion medicine with 2 years of experience 2) Specialist of a acupuncture and moxibustion medicine with more than 20 years of experience

HN5, TE17, and ST2. Details of the acupuncture treatments are provided in Table 1 (Table 1). Electroacupuncture treatment was administered 3 times a week, taking turns with pharmacopuncture. Selected electroacupuncture points were bilateral BL2- TE23, Ex-HN5-ST2. The machine for electroacupuncture was STN-110 set with stimulation of 3Hz, continuous for 20 minutes. Pharmacopuncture used was SBV10 (extracted and refined from bee toxin and mixed to 99.9% pure melittin 0.1mg/mL) manufactured in extramural herbal dispensaries. 1mL/cc syringe was used for 1mL administration of single sessions, and each dose administered 0.1mL intramuscularly. For physical therapy, ICT (interferential current therapy) was administered on the neck, and SSP-C (silver spike point) and manual therapy was administered on the facial region. Herbal medicine was given 3 times a day. Two kinds of herbal medicine were given (Table 2).

Evaluation

To measure the range of movement of adduction, abduction, up and down movement of both eyes, a ruler was used to measure in unit of mm with the patient's pupil set as the center. Also, eye movements in 9 cardinal positions were recorded in photographs 2 times a week. For evaluation of diplopia, a straight distance from the patient's glabella to where diplopia started to occur to where diplopia disappeared was measured. Also, this case report used the diplopia questionnaire that Jonathan et al [4, 5] had developed replacing the Goldmann test to evaluate the severity of diplopia (Appendix 1). For evaluation of the patient's subjective feeling of dizziness and diplopia, VAS scale was utilized. Evaluation was done by a resident trainee in acupuncture and moxibustion medicine.

Evaluation of range of eye movement

Primary eye measurements were taken on October 16, 2017. The right eye showed horizontal movement of 9 mm and vertical movement of 7 mm, while the left eye showed horizontal movement of 8 mm and vertical movement of 6 mm. Final measurements were obtained on November 23, 2017, which

Table 2. Herbal Compositions of 2 Herbal Medicines for Daily Dosage.

Pinellia, Atractylodis Mrocephalae, and Gastrodia Decoction (2017.10.16-2017.11.06)		Lycium-Chrysanthemum blood-nourishing decoction (2017.11.07-2017.11.23)	
Pinellia ternate	6g	Rehmanniae Radix Preparata	12g
Citrus tachibana	6g	Angelica gigas Nakai	6g
Hordeum vulgare Linné	6g	Paoniae Radix Alba	6g
Atractylodes macrocephala Koidzumi	4g	Lycium chinense Miller	6g
Massa Medicata Fermentata	4g	Cnidium officinale Makino	4g
Atractylodes japonica KOIDZ	2g	Chrysanthemum indicum	4g
Panax ginseng C. A. Meyer	2g	Liriope platyphylla F.T.Wang & T.Tang	4g
Astragalus membranaceus	2g	Tribulus terrestris L	4g
Gastrodia elata BLUME	2g	Ledebouriella seseloides WOLFF	4g
Poria cocos Wolf.	2g	Schizonepeta tenuifolia var. japonica	2g
Alisma canaliculatum A.Br. & Bouche	2g	Mentha arvensis var. piperascens Malinv. ex Holmes	2g
Zingiberis Rhizoma	1g	Glycyrrhiza uralensis	2g
Phellodendri Cortex	1g		

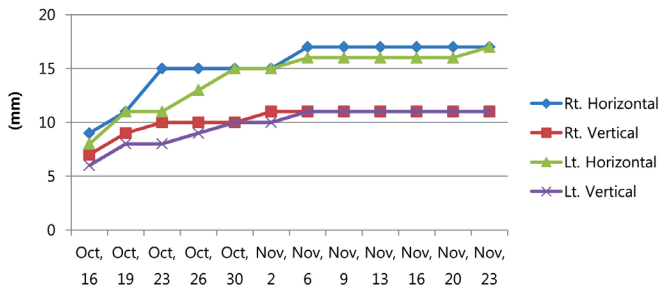


Fig. 1. Range of eye movement.

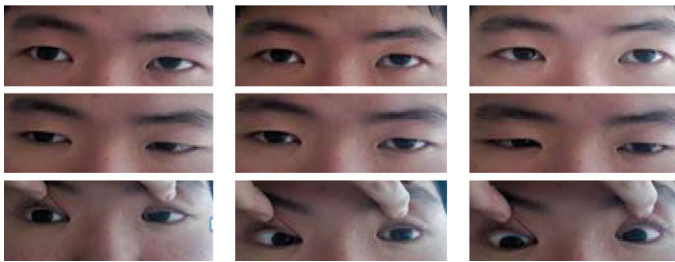

Fig. 2. Photographs of eye movement on 9 cardinal positions taken on October, 16, 2017.

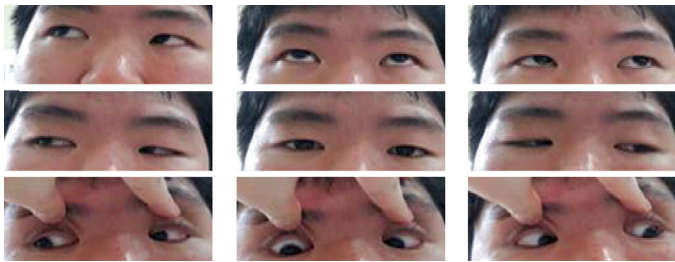


Fig. 3. Photographs of eye movement on 9 cardinal positions taken on October, 30, 2017.



Fig. 4. Photographs of eye movement on 9 cardinal positions taken on November, 23, 2017.

showed the right eye with horizontal movement of 17 mm and vertical movement of 11 mm while the left eye showed horizontal movement of 17 mm and vertical movement of 11 mm (Fig. 1).

Photographs of eye movements in 9 cardinal positions

Photographs of eye movements taken on November 23, 2017 on 9 cardinal positions showed difference compared to photographs taken on October 16, 2017 (Figs 2-4).

Measurement of distance of diplopia

The primary measurement of the straight distance from the patient’s glabella to where diplopia started to occur, and to where diplopia disappeared was recorded in all distance, while measurement on November, 23, 2017 was recorded in distance ranging from 59 cm to 67 cm (Table 3).

Evaluation of diplopia questionnaire

Primary score on the questionnaire performed on October, 16, 2017 was 25 where diplopia occurred in “always” in the 7 gaze positions. In the questionnaire performed finally on November, 23, 2017 and during admission, a score of 25 was recorded with frequency of diplopia recorded as “always”, showing no difference to the primary score.

VAS evaluation for diplopia and dizziness

Primary VAS scores evaluated on October, 16, 2017 for diplopia and dizziness were 9.2 and 1.8 respectively. Final scores on the 6 week of admission were 4.3 and 0.2 respectively, showing a reduction in VAS scores (Fig. 5).

Table 3. Distance of Diplopia.

Date	Distance (cm)
October, 16, 2017	All distance
October, 19, 2017	All distance
October, 23, 2017	All distance
October, 26, 2017	All distance
October, 30, 2017	All distance
November, 2, 2017	18-112
November, 6, 2017	21-81
November, 9, 2017	30-78
November, 13, 2017	44-75
November, 16, 2017	60-78
November, 20, 2017	65-75
November, 23, 2017	59-67

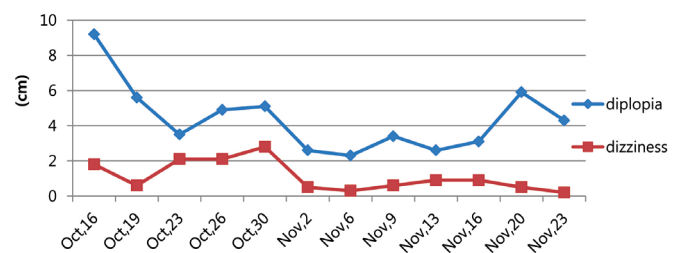


Fig. 5. VAS for diplopia and dizziness.

Discussion

MFS has a male to female occurrence in a 2:1 ratio, with an average age of about 43 years old, and with pediatric patients consisting of 14% of the total patients [2]. Anti-GQ1b antibody induces a secretory disorder of acetylcholine on the end of motor nerves, which is thought to be the etiological cause of eye movement disorder from muscle weakness in MFS [6]. The most common treatment uses anti-GQ1b IgG antibody that helps inhibit this auto-immune reaction [7].

Of the three main symptoms of MFS, ophthalmoplegia shows the slowest recovery with the recovery period being from 1 week to 20 weeks [8]. In this case report, the up and down eye movement started to show rapid recovery in the 2nd week of admission, reaching near complete recovery by the 4th week. The abduction and adduction also showed rapid recovery from the 1st week of admission reaching near complete recovery on the 4th week. There were also notable reductions in the distance that diplopia appears and VAS evaluation scores for diplopia and dizziness. In this study, the recovery period was shortened compared to recovery periods of MFS in previous studies. However, the patient showed diplopia in all gaze positions in equivalent frequency according to the questionnaire which suggests no improvement on diplopia.

This case report suggests that CKMT may have a role in treating eye movement disorders of MFS patients. Although the mechanism of CKMT remains unclear, one of the possible therapeutic mechanisms in this study is stimulation of acupuncture points near to the orbital wall. Acupuncture generates microinjury which increases local blood flow and facilitates healing [9]. Acupuncture points were adopted from previous studies. You et al [10] treated diplopia on acupuncture points like GV20, BL2, Ex-HN4, TE23, ST2, TE17, LI04, LR03, and ST36. Electroacupuncture promotes regeneration of nerve fibers and motor function recovery by decreasing the production of free radicals and regulating neuropeptide secretion [11]. And it is reported that bee venom has anti-inflammatory properties for disorders including atherosclerosis, diabetes-related endothelial damage, and autoimmune diseases [12,13,14]. It might have a similar effect on this disease. Lastly, *Lycium-Chrysanthemum blood-nourishing decoction* has been reported to have an effect on neuromyelitis optica and vision disorder [15]. According to our clinical judgement, the function of the eye may be improved by increasing the nourishing blood supply.

The limit of this study may be the uncertainty in determining which treatment had the main effect in this study because the patient received various CKMT therapies. Also, it is difficult to estimate the exact therapeutic effect of CKMT, because the duration of treatment in this case is within the period of MFS's natural recovery. Most symptoms of MFS start to recover within 3 weeks of onset and reach complete recovery within six months [8]. There are few studies comparing natural recovery with CKMT for treating MFS. This study is also limited as it is a retrospective studies. Prospective studies are required to examine the beneficial effect of CKMT for MFS in larger number of cases.

This case report suggests that CKMT may have a role in treating eye movement disorders and dizziness of MFS patients.

Conflicts of Interest

The authors have no conflicts of interest to declare.

References

- [1] Fischer M. An unusual variant of acute idiopathic polyneuritis (syndrome of ophthalmoplegia, ataxia and areflexia). N Engl J Med 1956;255:57-65.
- [2] Berlit P, Rakicky J. Miller Fischer syndrome. Review of the literature. J Clin Neuroophthalmol 1992;12:57-63.
- [3] Lo YL. Clinical and immunological spectrum of the Miller Fisher syndrome. Muscle Nerve 2007;36:615-627.
- [4] Jonathan MH, Leske DA, Kupersmith MJ. New Methods for Quantifying Diplopia. Ophthalmology 2005;112:2035-2039.
- [5] Holmes JM, Liebermann L, Hatt SR, Smith SJ, Leske DA. Quantifying Diplopia with a Questionnaire. Ophthalmology 2013;120:1492-1496.
- [6] Buchwald B, Weisjaupt A, Toyka KV, Dudel J. Pre-and postsynaptic blockade of neuromuscular transmission by Miller Fisher syndrome IgG at mouse motor nerve terminals. Eur J Neurosci 1998;10:281-290.
- [7] Odaka M, Yuki N, Hirata K. Anti-GQ1b IgG antibody syndrome; clinical and immunological range. J Neurol Neurosurg Psychiatry 2001;70:50-55.
- [8] Son MG, Ahn HS. Miller Fisher syndrome. J Korean Ophthalmol Soc 1997;38:1470-1479. [in Korean]
- [9] Cheng KJ. Neurobiological Mechanisms of Acupuncture for Some Common Illnesses: A Clinician's Perspective. J Acupunct Meridian Stud 2014;7:105-114.
- [10] Ryu JY, Lee KW, Cho MK, Cho HK, Yoo HR, Seol IC et al. Case report: Miller Fisher Syndrome. J Int Korean Med 2016;37:661-668. [in Korean]
- [11] Li YF, Li T, Zhang DW, Xue H, Chen D, Li C et al. The comprehensive Therapy of Electroacupuncture Promotes Regeneration of Nerve Fibers and Motor Function Recovery in Rats after Spinal Cord Injury. Evid Based Complement Alternat Med 2018;2018:7568697.
- [12] Lee WR, Kim SJ, Park JH. Bee venom reduces atherosclerotic lesion formation via anti-inflammatory mechanism. Am J Chin Med 2010;38:1077-1092.
- [13] Behroozi J, Divsalar A, Saboury AA. Honey bee venom decreases the complications of diabetes by preventing hemoglobin glycation. J Mol Liq 2014;199:371-375.
- [14] Wesselius T, Heersema DJ, Mostert JP. A randomized crossover study to bee sting therapy for multiple sclerosis. Neurology 2005;65:1764-1768.
- [15] Woo SJ, Shin JW, Jang WS, Baek KM. A Case Report of Treatment of a patient with Neuromyelitis Optica and Suffering from vision Disorder and Quadriplegia with Korean Traditional Medicine. J Intern Korean Med 2017;38:658-667.

Appendix 1. Questionnaire for Evaluation of Diplopia.

Questionnaire for evaluation of diplopia				
--	--	--	--	--

Gaze position	Always	Sometimes	Never	Score
Straight ahead in distance	6	3	0	
Up	2	1	0	
Down	4	2	0	
Right	4	2	0	
Left	4	2	0	
Reading	4	2	0	
Any position	1	1	0	

Total score :